viapath

King's College Hospital NHS
NHS Foundation Trust

A Comprehensive Next Generation Sequencing Gene Panel Focused on Unexplained Anaemia

F. Smith[1], D. Brawand[1], L. Steedman[1], M. Oakley[1], C. Wall[1], P. Rushton[1], K. Sibson[2], M. Allchurch[3], C. Hemmaway[3], R. Ireland[4], S-L. Thein[5,6], D. Rees[4,5], B. Clark[1,5]

Introduction

Congenital anaemia is difficult to diagnose once common causes have been excluded; for example 80% of congenital non-spherocytic haemolytic anaemia cases are undiagnosed once pyruvate kinase and G6PD deficiencies have been excluded using phenotypic analysis.

We have developed a **comprehensive Red Cell Gene Panel** for the molecular diagnosis of unexplained anaemia and other red blood cell disorders, screening all genes known to be associated with each disorder. The panel is split into several virtual sub-panels to focus analysis, which can be analysed in any combination relevant to the referral.

The Red Cell Gene Panel:

- Haemoglobinopathy
- Membranopathy
- Enzymopathy
- Congenital dyserythropoeitic anaemia (CDA)
- Congenital erythrocytosis
- Diamond-Blackfan anaemia
- General anaemia
- Porphyria
- Iron metabolism

Next Generation Sequencing:

Figure 1: Next Generation Sequencing process

a) Automated Laboratory workflow:

Library prep
3 days

DNA sequencing
1 day

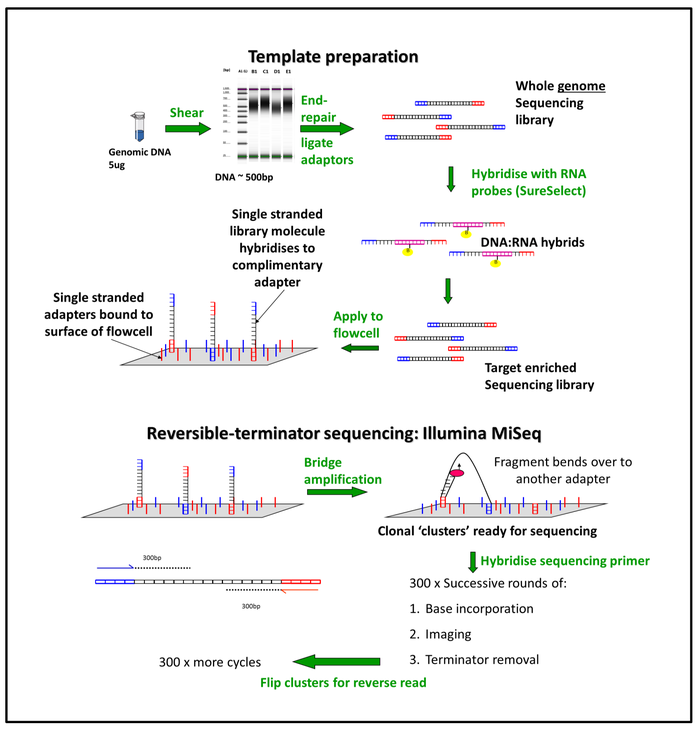

b) Data analysis:

30 minutes

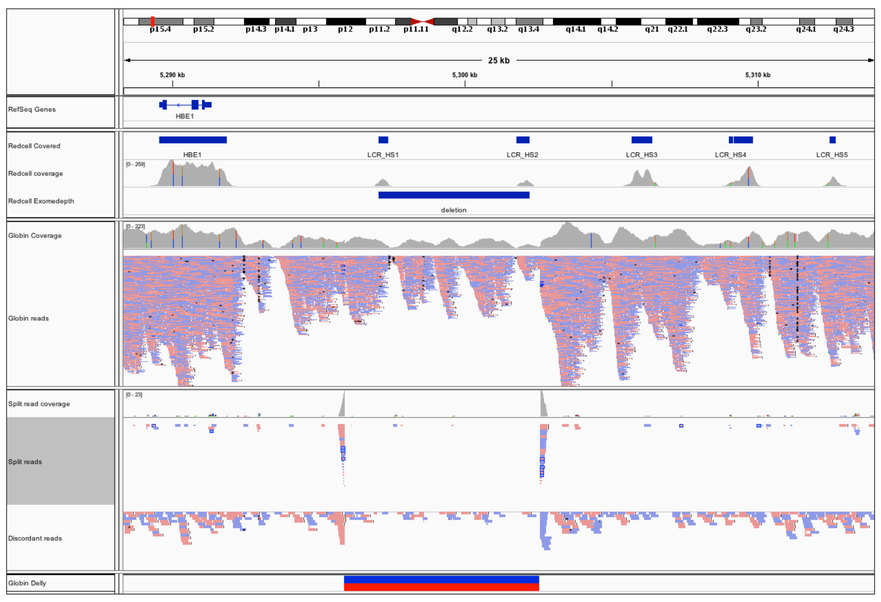

c) Variant confirmation:

2 days

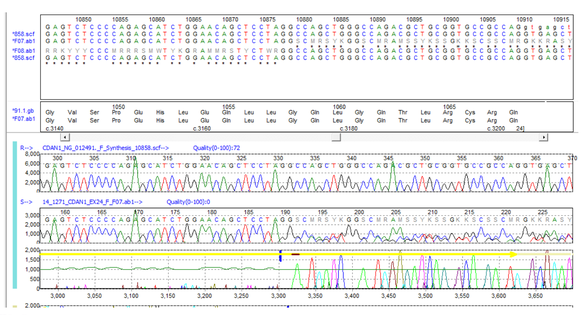

d) Interpretation & reporting:

1 day

Case studies

The following three cases highlight the clinical utility of the Red Cell Gene Panel and show the range of referral reasons.

Case 1 – Haemoglobinopathy

An Italian girl presented with a severe form of microcytic anaemia. Using the Red Cell Gene panel we identified two pathogenic variants, one of which was not detectable by routine HBB sequencing:

Figure 2: Case 1 pedigree

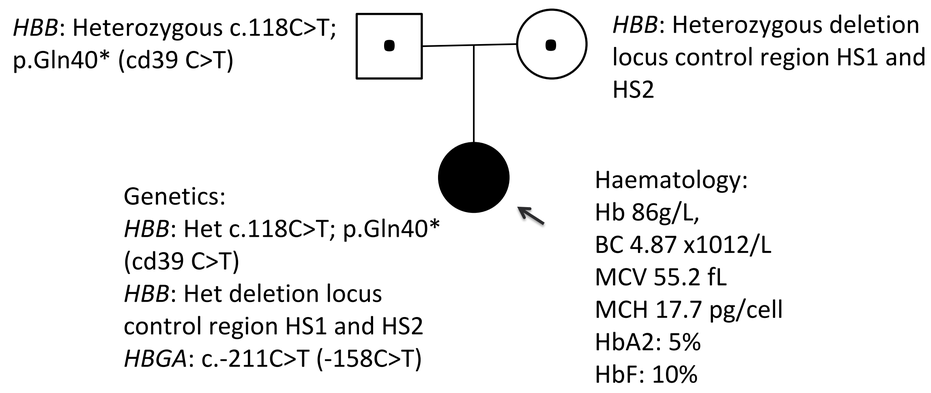

The combination of this mild down regulation of the beta globin locus caused by the locus control region deletion in combination with the c.118C>T β^0 thalassemia variant caused her severe phenotype.

Case 2 – Congenital dyserythropoeitic anaemia type 1

The post mortem report from an infant who died at age 3 days showed extensive extramedullary hematopoiesis and severe anaemia. The DNA sample from the proband was relatively small so the parental samples were analysed using the Red Cell Gene Panel. Both parents were found to carry a pathogenic variant in CDAN1 and Sanger Sequencing showed that the child had inherited both mutations, and a diagnosis of CDA type 1 was confirmed.

Figure 3: Case 2 pedigree

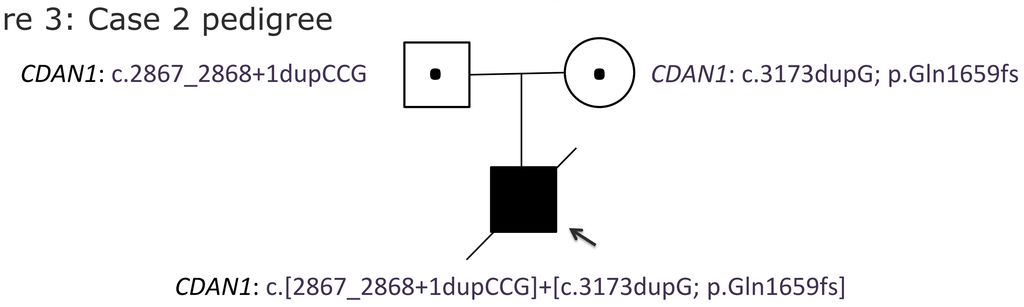

Case 3 – Hereditary pyropoikilocytosis

A male Caucasian child of <1 year presented with haemolysis (LDH 539 IU/L, total bilirubin 39 umol/L), haematology (Hb 92g/L, MCV 84.4, MCH 28.9, Absolute Retic count 313.8x10^9/L); his film showed marked anisopoikilocytes, microspherocytes and polychromasia, see figure 4c. He had frontal bossing and a palpable spleen and had suffered several infections, the child was transfused once. His father's film showed elliptocytes (figure 4b), FBC (Hb 127g/L, MCV 89.6, MCH 30.6, Absolute Retic count 230.5x10^9/L) but he had never been transfused. The mother's FBC was normal (Hb 113g/L, MCV 87.0, MCH 29.2, Absolute Retic count 48.4x10^9/L) but her film also showed elliptocytes (figure 4a) . Analysis using the red cell panel found the child to be compound heterozygous for c.83G>A; p.Arg28His and c.[5572C>G; 6531-12C>T]; p.[Leu1858Val;?] in the *SPTA1* gene, suggesting the diagnosis of hereditary pyropoikilocytosis. The c.83G>A; p.Arg28His mutation was inherited from the father and the c.[5572C>G; 6531-12C>T]; p.[Leu1858Val;?] low expression allele was inherited from the mother, who was homozygous.

Figure 4: Case 3 blood films

a) Mother b) Father c) Proband

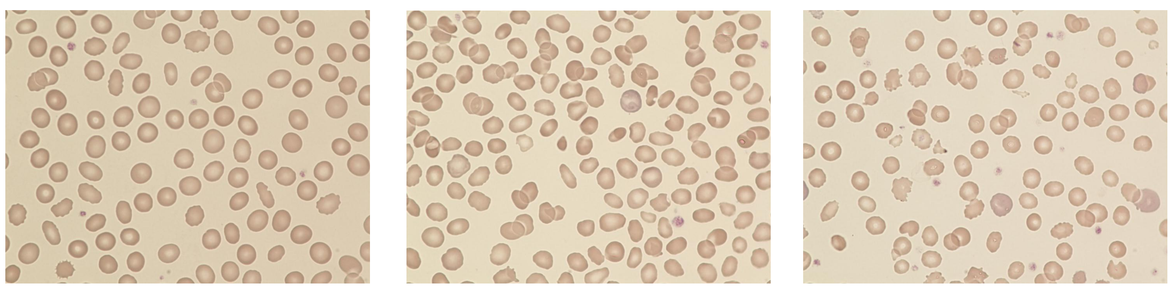

Conclusions:

Identifying pathogenic variants in these families is important as it facilitates prognosis and treatment, and allows prenatal diagnosis to be offered in future. To date the panel has assessed 10 cases of anemia with unknown cause and has made a definitive diagnosis in 8 (80%).

Author affiliations:
[1] Dept of Molecular Pathology, Viapath at King's College Hospital, Denmark Hill, London, SE5 9RS, UK
[2] Dept of Haematology, Great Ormond Street Hospital, London, WC1N 3JH, UK
[3] Dept of Haematology, Queen's Hospital, Rom Valley Way, Romford, Essex, RM7 0A, UK
[4] Dept of Haematological Medicine, King's College Hospital, Denmark Hill, London, SE5 9RS, UK
[5] King's College London, Molecular Haematology, Division of Cancer Studies, London, SE5 9RS, UK
[6] National Heart, Lung and Blood Institute/NIH, Sickle Cell Branch, Bethesda, USA

For more information please contact Dr Barnaby Clark (barnaby.clark@nhs.net) or Frances Smith (frances.smith17@nhs.net).

Please take a leaflet or contact the laboratory for a list of the genes included in each sub-panel.